



RETINA WORLD CONGRESS

Volumetric Macular Fluid Analysis of the Impact of a Single Axitinib Intravitreal Injection (OTX-TKI) from the HELIOS Clinical Trial for Diabetic Retinopathy

Carl Danzig, MD¹

On behalf of the HELIOS Investigators, with OCT and Leakage analyses based on the findings of Justis P. Ehlers, MD and his Cole Eye research team

Allen Hu, MD²; Arshad Khanani, MD³; Dennis Marcus, MD⁴; Mark Barakat, MD⁵; Veeral Sheth, MD⁶; Brian Berger, MD⁷; Michael Singer, MD⁸; Charles Wykoff, MD, PhD⁹; David Brown, MD¹⁰

¹Rand Eye Institute, Deerfield Beach, FL, USA; ²Cumberland Valley Retina Consultants, Hagerstown, MD, USA; ³Sierra Eye Associates, Reno, NV, USA; ⁴Southeast Retina Center, Augusta, GA, USA; ⁵Retina Macula Institute of Arizona, Phoenix, AZ, USA; ⁶University Retina, Lemont, IL, USA; ⁷Austin Clinical Research, Austin, TX, USA; ⁸Medical Center Ophthalmology Associates, San Antonio, TX, USA; ⁹Retina Consultants of Texas, The Woodlands, TX, USA; ¹⁰Retina Consultants of Texas, Bellaire, TX, USA;



Disclosures and Acknowledgements

FINANCIAL DISCLOSURES (Carl Danzig, MD)

Research Grant: 4DMT, Adverum, Alexion, Annexon, Aviceda, Bayer, Boehringer Ingelheim, Curacle, EyeBio, Eyepoint, Genentech, Gyroscope, IvericBio/Astellas, Kodiak, Novartis, Ocular Therapeutix, Oculis, Regeneron, RegenxBio, Rezolute, Roche, Stealth, Unity

Consultant: 4DMT, Abbvie, Adverum, Alimera, Galimedix, Genentech, Heidelberg, IvericBio/Astellas, Kodiak, Novartis, Ocular Therapeutix, Oculis, Regeneron, Regenxbio, Stealth

Speaker: Genentech, IvericBio/Astellas

STUDY AND PRODUCT DISCLOSURES

The following presentation discusses an investigational drug candidate, AXPAXLI™ (also referred to as OTX-TKI), in development. OTX-TKI's efficacy and safety profiles have not been established, and it has not been approved for marketing by the U.S. Food and Drug Administration (FDA) or any other health agency.

Ocular Therapeutix sponsored this clinical trial.

ACKNOWLEDGEMENTS

OCT Analysis based on the findings of Justis P. Ehlers, MD and his Cole Eye research team

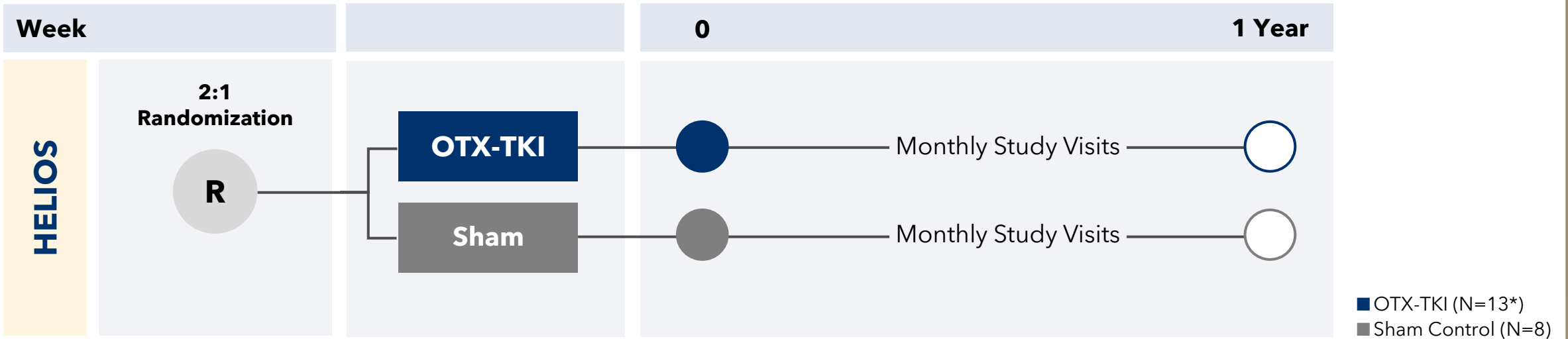
HELIOS Phase 1 Study of OTX-TKI in NPDR



DESIGN

Multi-center, double-masked, randomized, parallel group study of OTX-TKI in moderately-severe to severe NPDR without CI-DME.

TRIAL SCHEMATIC



STUDY OUTCOMES

PRIMARY: Safety and tolerability of OTX-TKI

SECONDARY: DRSS changes, rescue therapy, BCVA, and CSFT changes

*14 were enrolled, with one death unrelated to treatment prior to week 24 visit.

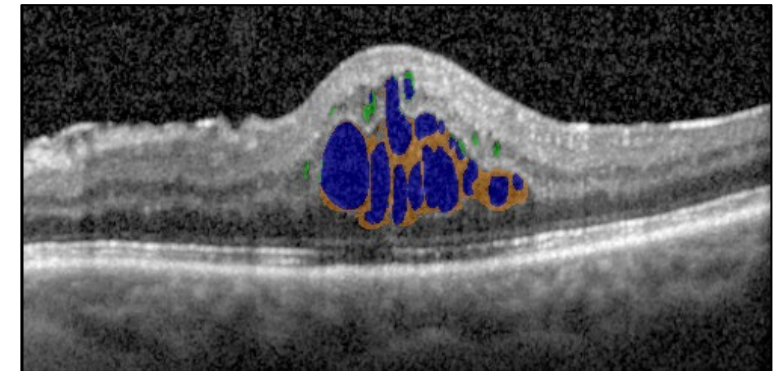
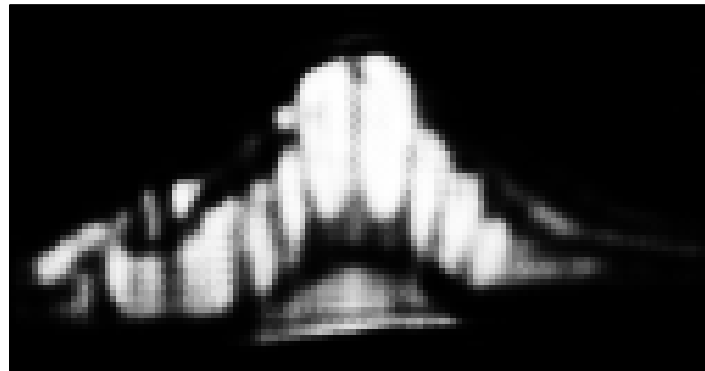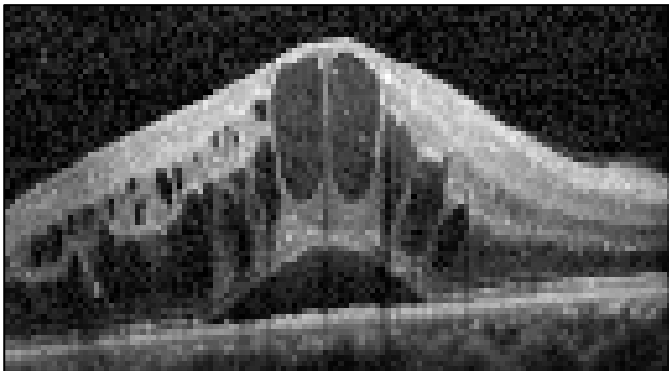
Abbreviations: BCVA (Best-corrected visual acuity); CI-DME (Center-involved diabetic macular edema); CSFT (Central subfield thickness); DRSS (Diabetic retinopathy severity scale); NPDR (Non-proliferative diabetic retinopathy).

Multi-Layer and Fluid Feature OCT Analysis

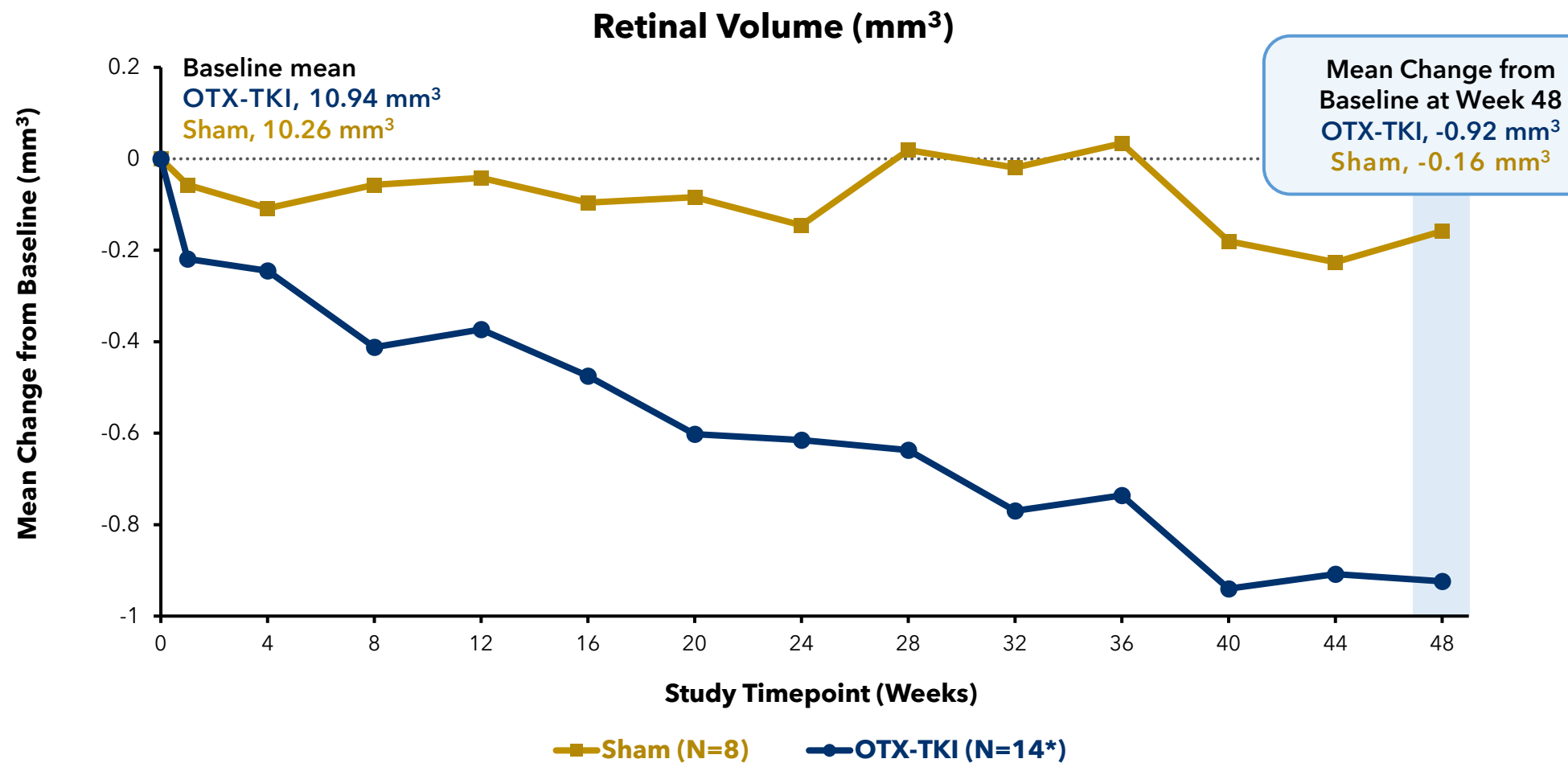
Acknowledgement

OCT and Leakage analyses based on the findings of Justis P. Ehlers, MD and his Cole Eye research team

- Post-hoc analysis assessment for **advanced OCT feature analysis**
- Multi-model **machine learning enhanced segmentation and feature extraction** performed with certified reader validation across macular cube
- Analysis features assessed:
 - Intraretinal fluid
 - Subretinal fluid
 - Retinal thickness (i.e., ILM-RPE)

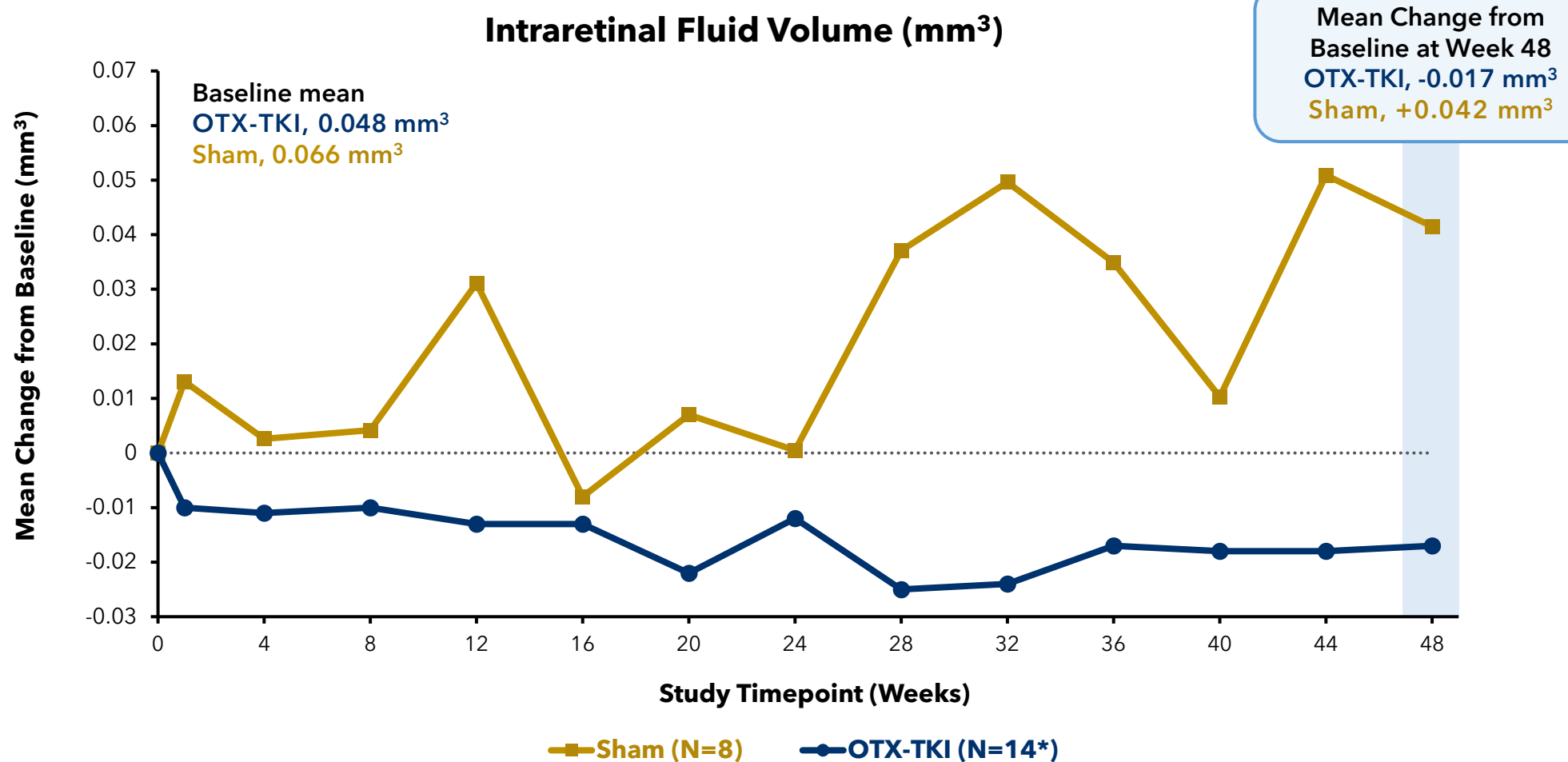


OTX-TKI Patients Consistently Had Greater Reductions from Baseline in Retinal Volume Compared to Sham



*14 were enrolled, with one death unrelated to treatment prior to week 24 visit.

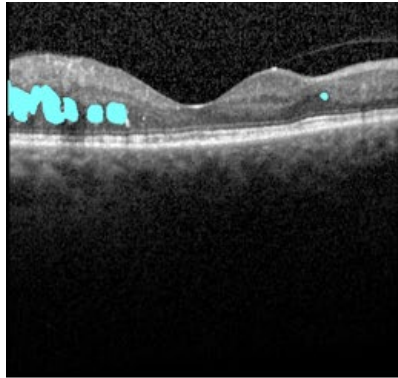
Sustained Control of Intraretinal Fluid in OTX-TKI Patients Over 48 Weeks



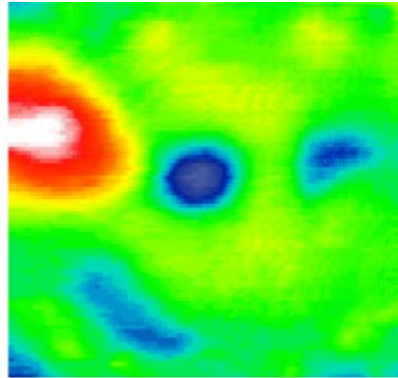
*14 were enrolled, with one death unrelated to treatment prior to week 24 visit.

Case Example: Sham Patient

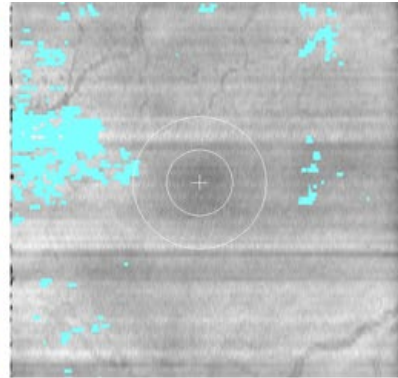
BASELINE




Foveal B-Scan



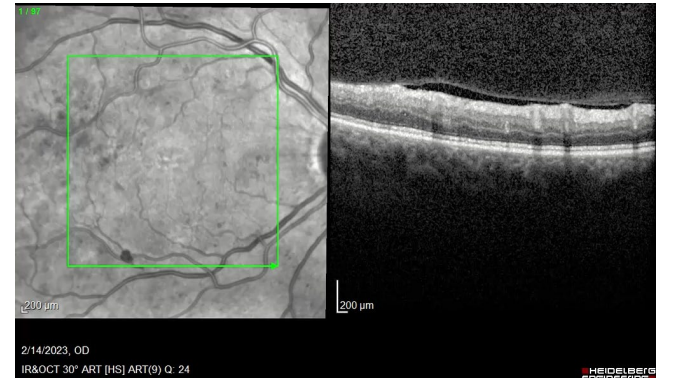
ILM/RPE Thickness Map



IRF Map

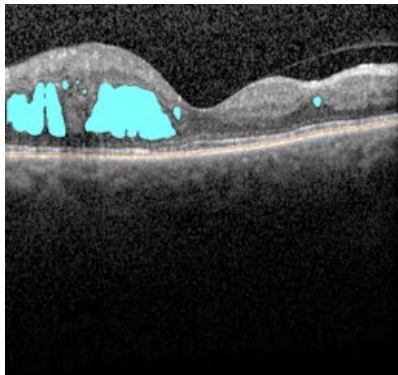


Fluid Thickness Map

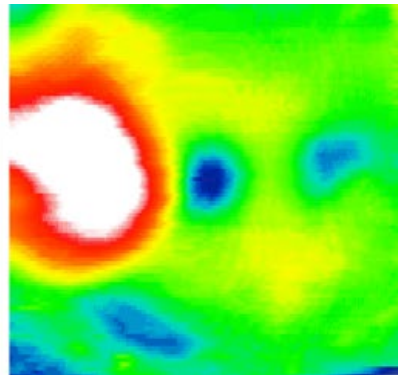


Macular Scan


WEEK 48



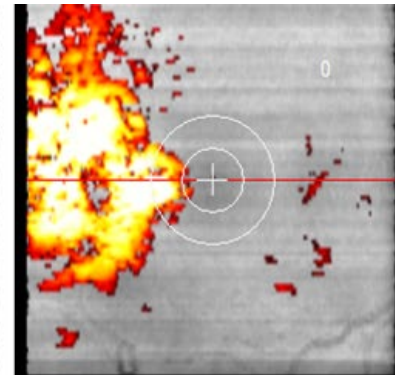
Foveal B-Scan



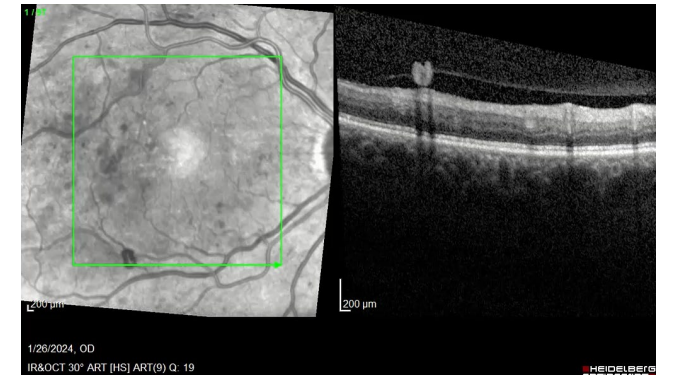ILM/RPE Thickness Map



IRF Map



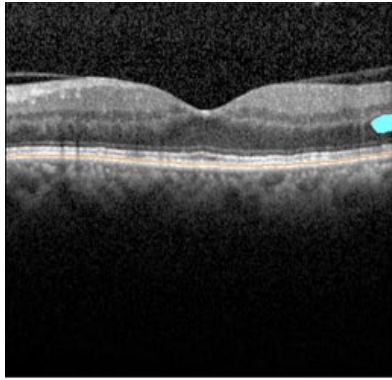
Fluid Thickness Map



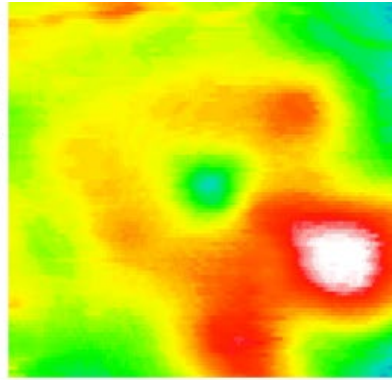
Macular Scan

Case Example: OTX-TKI Patient


BASELINE



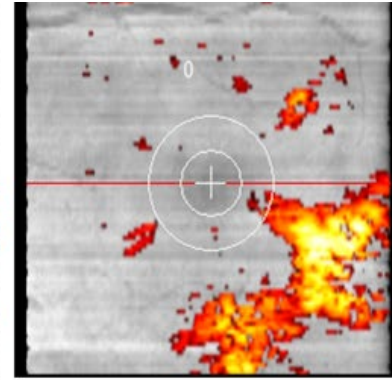
Foveal B-Scan



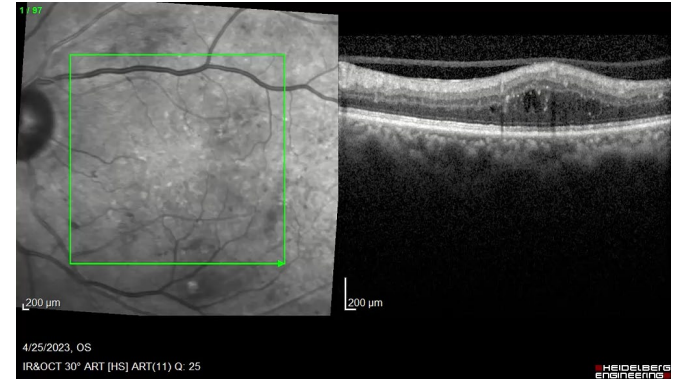
ILM/RPE Thickness Map



IRF Map

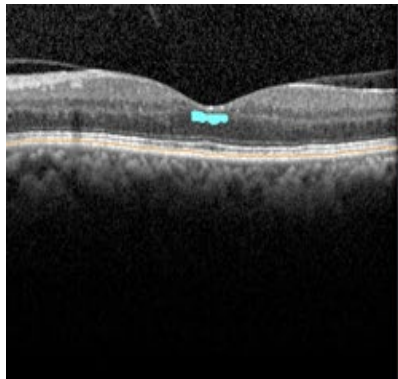


Fluid Thickness Map




Macular Scan

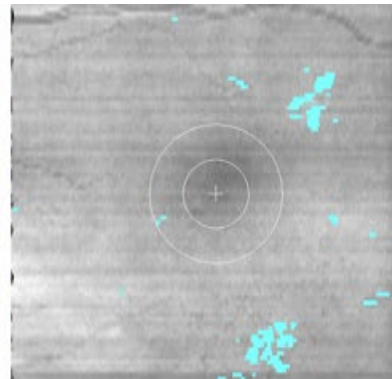
WEEK 48




Foveal B-Scan



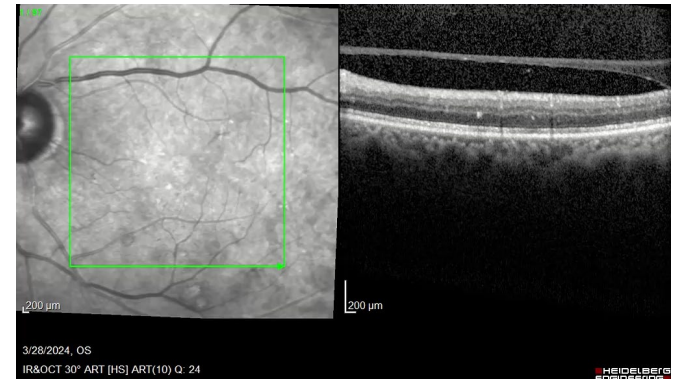
ILM/RPE Thickness Map



IRF Map



Fluid Thickness Map



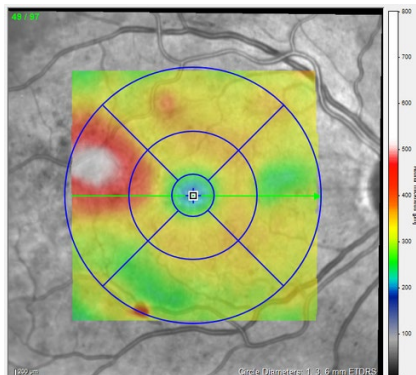
Macular Scan

Case Example: Sham Patient, 61yo Male

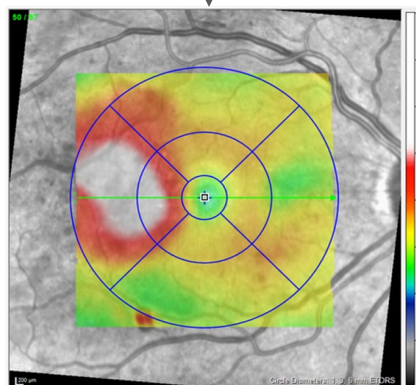
Developed CI-DME by Week 48

MACULAR THICKNESS MAPS

Baseline



Week 48



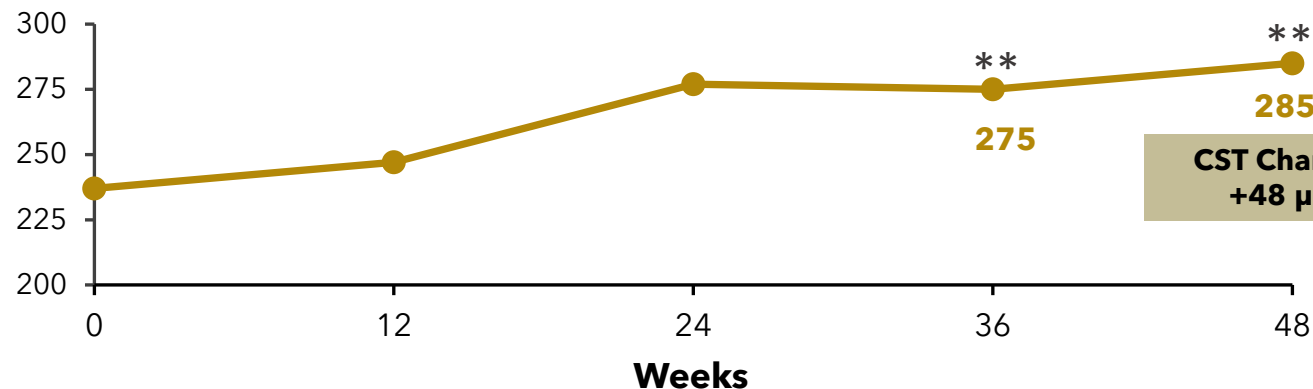
DRSS SCORE

53
Baseline

53
24 Weeks

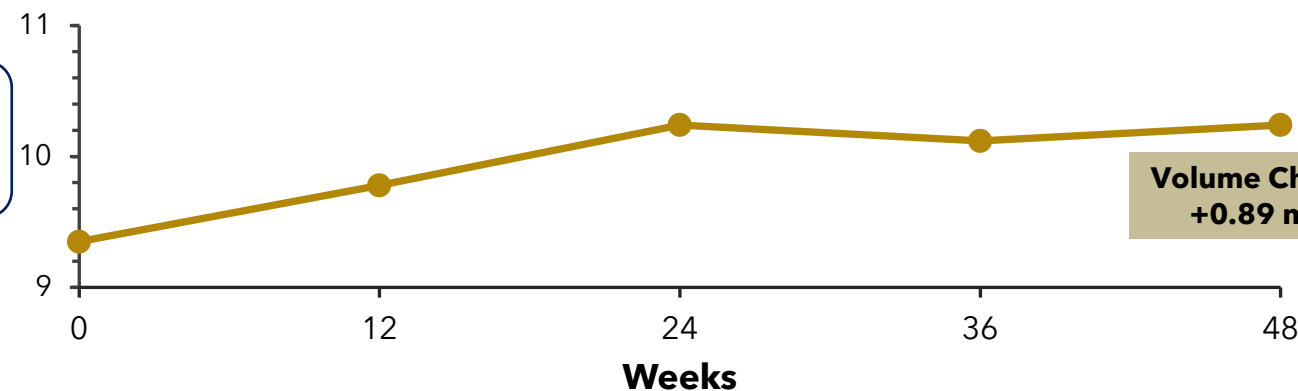
53
48 Weeks

CST (μm)



CST Change: +48 μm

MACULAR VOLUME (mm³)



Volume Change: +0.89 mm³

*Sham Patient denotes Patient 11-008

**OCT CI-DME

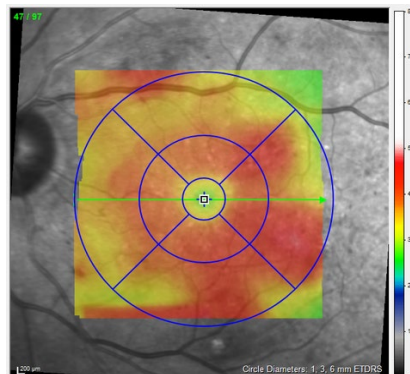Abbreviations: DME (diabetic macular edema), DRSS (diabetic retinopathy severity scale), CST (central subfield thickness), OCT ci-DME (optical coherence tomography center-involved- diabetic macular edema)

Case Example: OTX-TKI Patient, 60yo Male

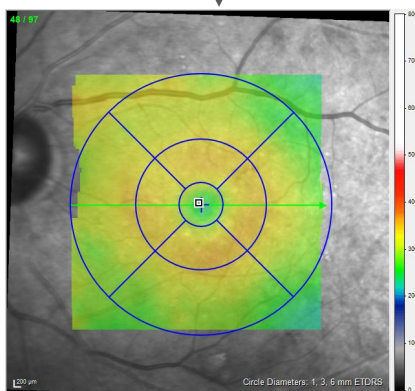
1-step DRSS Improvement by Week 48

MACULAR THICKNESS MAPS

Baseline



Week 48



DRSS SCORE

53
Baseline

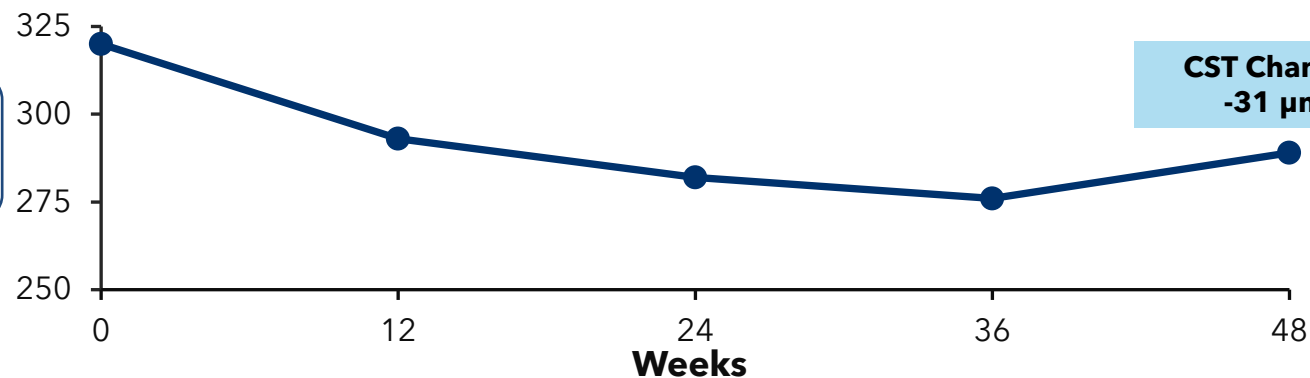
1-step improvement

47
24 Weeks

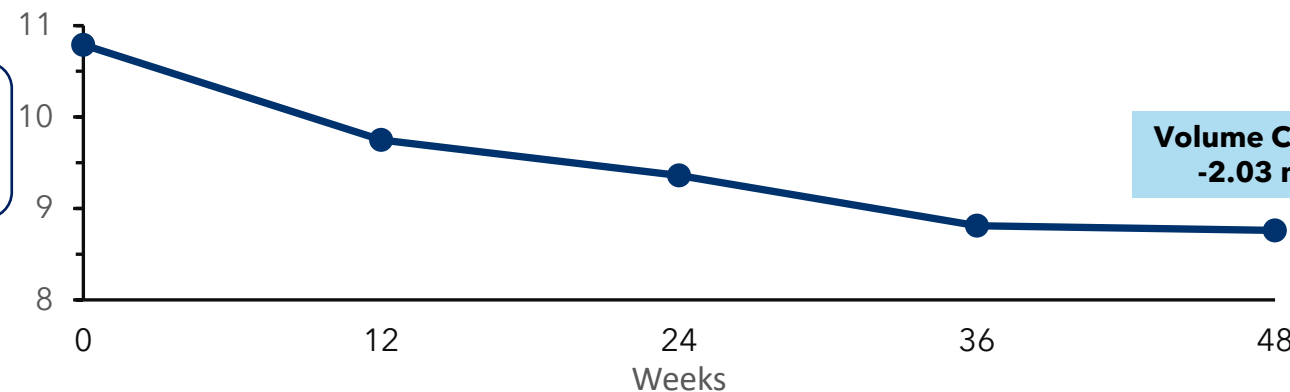
1-step improvement

47
48 Weeks

CST (μm)



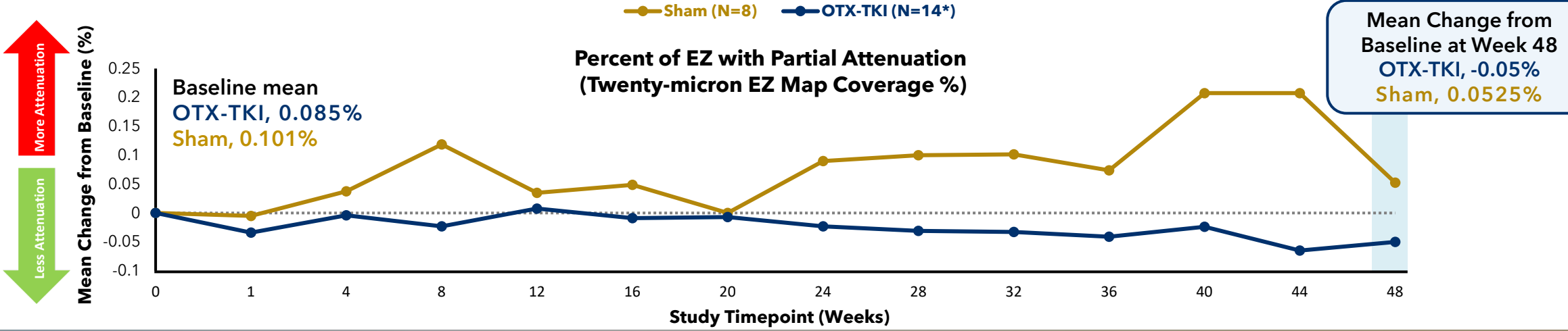
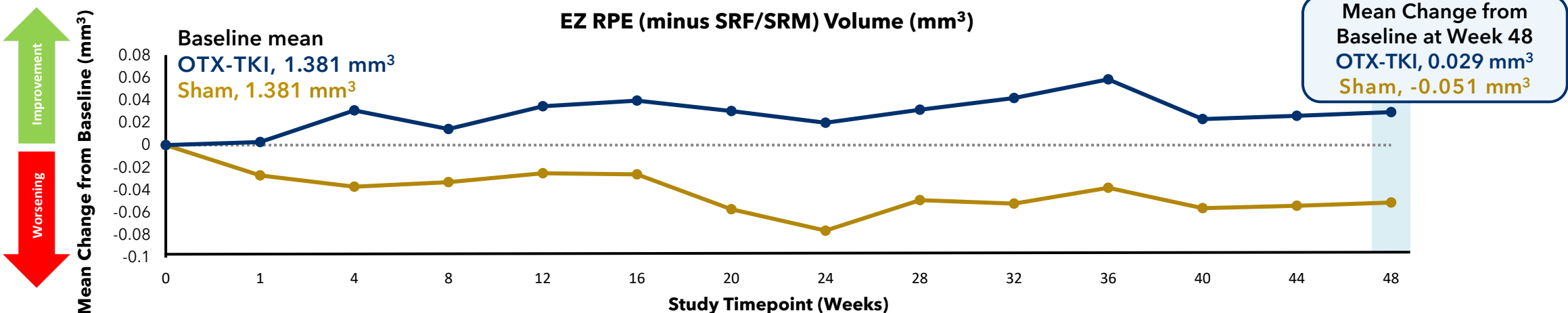
MACULAR VOLUME (mm³)



*OTX-TKI Patient denotes Patient 11-008

Abbreviations: DME (diabetic macular edema), DRSS (diabetic retinopathy severity scale), CST (central subfield thickness), OCT ci-DME (optical coherence tomography center-involved- diabetic macular edema)

Stabilization of EZ Integrity was Observed in OTX-TKI-Treated Patients Compared to Sham



Emerging quantitative OCT evidence in patients with no DR vs. early DR indicates metabolic changes increase photoreceptor abnormalities¹

*14 were enrolled, with one death unrelated to treatment prior to week 24 visit.; DR: diabetic retinopathy
¹Le D, Son T, Lim JI, Yao X. QUANTITATIVE OPTICAL COHERENCE TOMOGRAPHY REVEALS ROD PHOTORECEPTOR DEGENERATION in EARLY DIABETIC RETINOPATHY. Retina. 2022 Aug 1;42(8):1442-1449. doi: 10.1097/IAE.0000000000003473. PMID: 35316256; PMCID: PMC9329162.

Key Takeaways of Quantitative Analysis of Macular Volumes and EZ Integrity from HELIOS Study

Consistent improvement in fluid metrics was observed in OTX-TKI-treated patients compared to sham

No OTX-TKI patients developed PDR or CI-DME through 48 weeks (37.5% in sham group)

Stabilization of EZ integrity was observed in OTX-TKI-treated patients compared to sham

These results support the potential of OTX-TKI as a long-acting treatment option for diabetic retinopathy, warranting further clinical investigation

Thank you.